

Lamotrigine-Induced Toxic Epidermal Necrolysis Treated With Intravenous Immunoglobulin and Amniotic Membranes

Rodrigo Schwartz, MD; Esteban Avello, MD; Francis Palisson, MD; Servicio de Dermatología, Hospital Clínico Universidad de Chile, and Departamento de Dermatología, Clínica Las Condes (Dr Schwartz), Debra-Chile Foundation (Drs Schwartz, Avello, and Palisson), and Departamento de Dermatología, Facultad de Medicina, Universidad del Desarrollo-Clinica Alemana (Dr Palisson), Santiago, Chile

The Cutting Edge: Challenges in Medical and Surgical Therapeutics

Toxic epidermal necrolysis is a life-threatening skin disease. Our case is an attempt to improve its outcome using a novel adjuvant treatment plan.

REPORT OF A CASE

A 36-year-old Chilean woman with depressive disorder was prescribed treatment with lamotrigine starting at a dosage of 25 mg/d and increasing 25 mg per week. When she reached 75 mg/d at the third week, she presented with an acute abdominal skin eruption. She was evaluated in an emergency department and received 1 dose of sodium phosphate betamethasone and dexchlorpheniramine maleate, 5.3 mg, intravenously, which resulted in partial relief of symptoms for a few hours. The following day she presented with fever with a body temperature up to 38.5°C and a generalized erythematous maculopapular skin eruption, along with few bullae on friction-prone areas and erosions on her oral mucosa and lips. In the next hours, the eruption rapidly became bullous with extensive epidermal detachment affecting approximately 50% of the body surface area (**Figure 1**).

Initial laboratory workup showed anemia (hemoglobin level, 11 g/dL), leukopenia (3500/mm³), high band neutrophil count (47%), mild thrombocytopenia (121 000/mm³), high erythrocyte sedimentation rate (44 mm/h), and high C-reactive protein (16 mg/dL). Initial liver and kidney function tests revealed no abnormal findings. (To convert hemoglobin to grams per liter, multiply by 10.0; to convert C-reactive protein to nanomoles per liter, multiply by 9.524.)

The patient was admitted to an intensive care unit for supportive care with a diagnosis of toxic epidermal necrolysis (TEN), and treatment with intravenous immunoglobulin (IVIg) at a dosage of 1 g/kg/d was initiated. An insufficient response was observed after 5 days of IVIg.

THERAPEUTIC CHALLENGE

Toxic epidermal necrolysis is a rare, life-threatening mucocutaneous disease with extensive epidermal detach-

ment. In most cases it is drug related.¹ One of the most important prognostic factors for its high mortality (15%-40%) is the extent of the epidermal detachment.² Several treatment options have been tried for this severe hypersensitivity manifestation, including use of systemic corticosteroids, thalidomide, pentoxifylline, cyclosporine, cyclophosphamide, and IVIg, with different and controversial results.

SOLUTION

It was then decided to cover the areas of epidermal detachment with 4 fresh amniotic membranes (**Figure 2**), previously tested for human immunodeficiency virus, rapid plasma reagin, cytomegalovirus, Chagas disease, human T-lymphotropic virus 1 (HTLV-1), hepatitis B, and hepatitis C. The same tests were performed in our patient, and findings were positive for HTLV-1 but not the other markers. The amniotic membranes were obtained at the time of a birth by cesarean delivery, rinsed with isotonic sodium chloride solution, and conserved for 12 hours before use in a saline medium with added penicillin. The amniotic membranes were placed under ster-

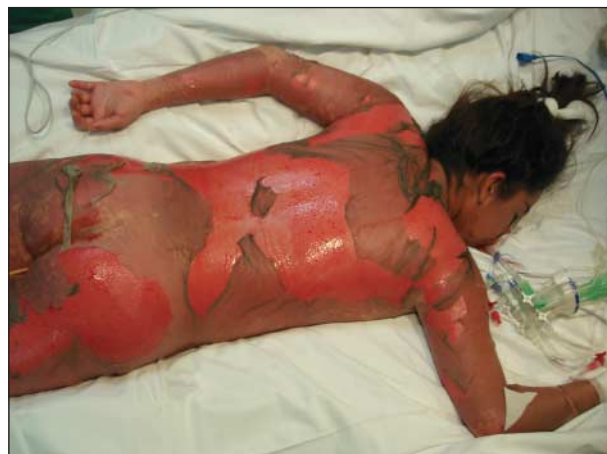

Figure 1. Extensive epidermal detachment affecting approximately 50% of the body surface area.

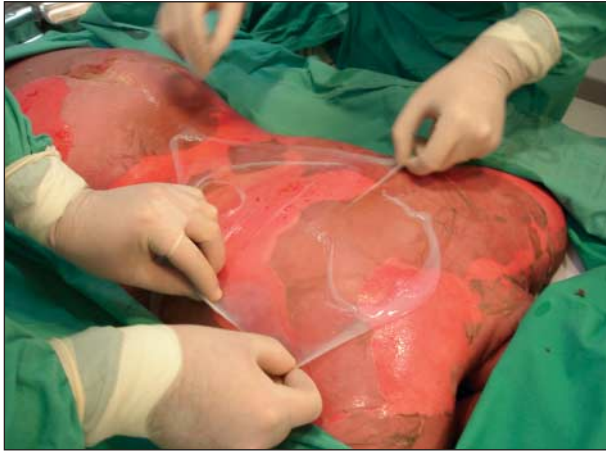


Figure 2. Areas of epidermal detachment covered with fresh amniotic membranes.

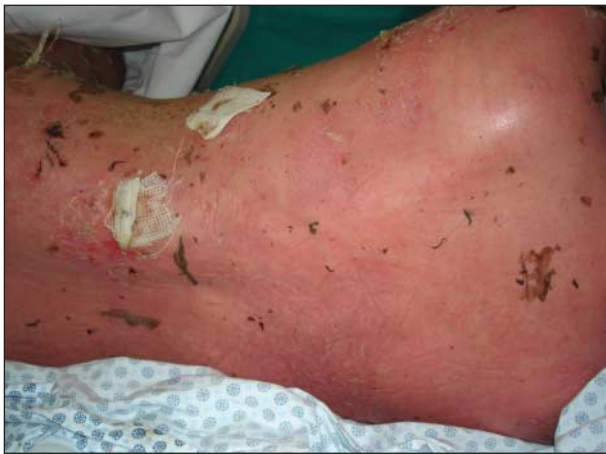

Figure 3. Complete reepithelization of the affected skin was observed 5 days after the membrane placement.

ile conditions. The patient was kept in a prone position for 24 hours, until the amniotic membranes dried and consequently fixed to the skin. Subsequently she was turned over to a supine position and amniotic membranes were applied on the other side. She was intubated during the whole procedure, and IVIG was maintained concurrently with the application of the amniotic membranes. The findings from the physical examination and laboratory workup showed that she improved dramatically during the following 24 hours with a marked decrease in exudation from denuded areas and control of her pain. A complete reepithelization of the affected skin was observed 5 days after the membrane placement (**Figure 3**). We obtained a skin biopsy sample from an area with skin detachment on hospital day 1, before IVIG was started, which confirmed the diagnosis of TEN (**Figure 4**). We also obtained biopsy specimens from an amniotic membrane-covered area with underlying nondetached epidermis on hospital day 10 (5 days after the amnion placement), which showed a nonnecrotic epidermis covered by amniotic membrane remnants and serous exudate. The dermis had a scarce inflammatory infiltrate (**Figure 5**).

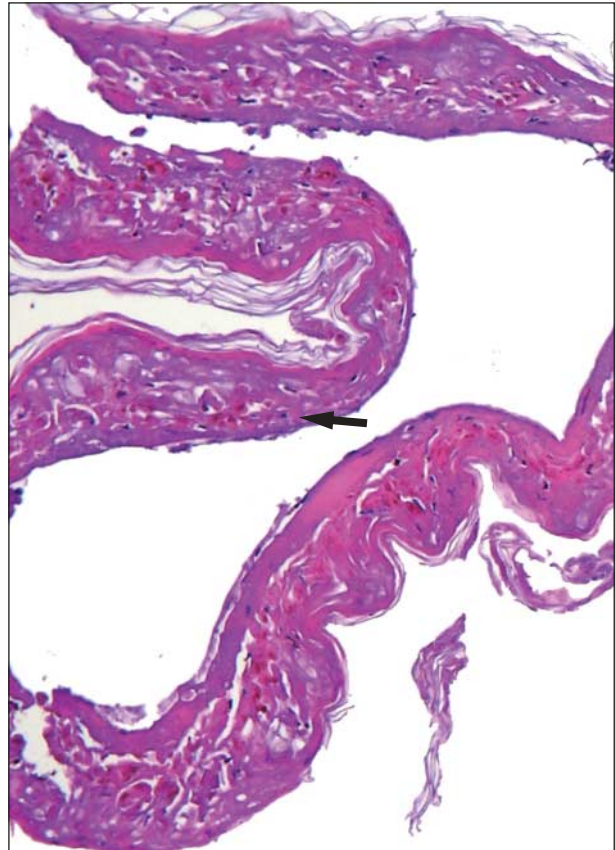


Figure 4. Light microscopic image obtained on hospital day 1, before intravenous immunoglobulin administration, showing the epidermis with extensive necrosis and intraepidermal lymphocytes (arrow) (hematoxylin-eosin, original magnification $\times 40$).

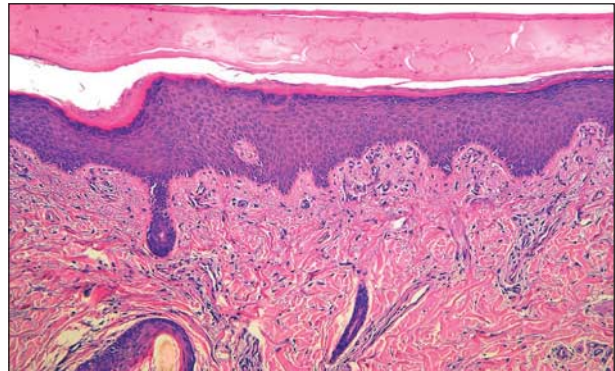


Figure 5. Nonnecrotic epidermis covered by amniotic membrane obtained on hospital day 10 showing epidermis with mild orthokeratosis and mild hypergranulosis, and slight spongiosis. Covering the epidermis there is evidence of amniotic membrane remnants with serous exudate. The dermis has a scarce inflammatory infiltrate (hematoxylin-eosin, original magnification $\times 40$).

COMMENT

There are few reports that suggest the clinical application of amniotic membranes on skin diseases involving loss of epidermal integrity. Chronic ulcers,³⁻⁵ burns,⁶⁻⁹ and skin graft donor sites¹⁰ have been treated successfully with amniotic membranes. In the past decade, there have been reports of its application on epidermolysis bullosa,¹¹ as a cover for microskin grafts,¹² and as a covering follow-

ing dermabrasion and laser treatment.¹³ Although good results have been observed, most reports consist of single cases and small uncontrolled series. Regarding TEN and amnion, to our knowledge there has been only 1 report, which described a 6-year-old child with TEN who was effectively treated with amniotic membranes on denuded areas.¹⁴ To our knowledge, there are no other reports on amnion as a coadjuvant treatment for skin detachment in Johnson-Stevens syndrome and TEN.

The extent of the epidermal detachment is one of the main prognostic factors in TEN.² Consequently, therapeutic options that minimize loss of epidermal integrity should be considered in the treatment of TEN. Intravenous immunoglobulin has an antiapoptotic effect on keratinocytes, which might explain its efficacy in treating TEN.¹⁵

Amniotic membrane forms the innermost layer of the placenta and consists of a single epithelial layer, a thick basement membrane, and an avascular stromal matrix. There are several studies^{16,17} that have demonstrated that amniotic epithelial cells contain growth factors that could be effective in stimulating epithelial growth. Other features that have been described include enhancement of granulation tissue production,³ production of angiogenic and anti-inflammatory proteins, antifibrotic properties,¹⁸ induction of macrophage apoptosis,¹⁹ and a decrease in wound infection rates.⁶ It has also been reported¹³ that amnion serves as a matrix for the growth of keratinocytes. Finally, reduction in pain, improved cosmetic appearance, shorter hospital stays, reduced cost, and patient acceptability have also been documented.²⁰

In our patient, a dramatic improvement was observed 24 hours after amniotic membrane placement. This observation could be explained by a multifactorial effect: growth factors promoting epithelial growth and anti-inflammatory mediators that may lead to an antiapoptotic effect. In addition, the membranes serve as a physical barrier against excess fluid and protein loss and protection from external biological and physical injury. Although more studies are needed to make definite conclusions, we believe that amniotic membranes in association with IVIG may prove to be effective coadjuvant treatments in the treatment of TEN.

Accepted for Publication: July 30, 2007.

Correspondence: Rodrigo Schwartz, MD, Department of Dermatology, University of Chile, Santos Dumont 999, Independencia, Santiago, Chile (schwartz.rodriigo@gmail.com).

Author Contributions: Drs Schwartz, Avello, and Palisson had full access to all of the data in the study and take responsibility for the integrity of the data and the accuracy of the data analysis. *Study concept and design:* Palisson. *Acquisition of data:* Schwartz, Avello, and Palisson. *Analysis and interpretation of data:* Schwartz, Avello, and Palisson. *Drafting of the manuscript:* Schwartz and Palisson. *Critical revision of the manuscript for important intellectual content:* Schwartz, Avello, and Palisson. *Administrative, technical, and material support:* Avello and Palisson. *Study supervision:* Palisson.

Financial Disclosure: None reported.

REFERENCES

- Roujeau JC, Kelly JP, Naldi L, et al. Medication use and the risk of Stevens-Johnson syndrome and toxic epidermal necrolysis. *N Engl J Med*. 1995;333(24):1600-1609.
- Paul C, Wolkenstein P, Adle H, et al. Apoptosis as a mechanism of keratinocyte death in toxic epidermal necrolysis. *Br J Dermatol*. 1996;134(4):710-714.
- Troensegaard-Hansen E. Amniotic grafts in chronic skin ulceration. *Lancet*. 1950;1(6610):859-860.
- Mermet I, Pottier N, Sainthillier JM, et al. Use of amniotic membrane transplantation in the treatment of venous leg ulcers. *Wound Repair Regen*. 2007;15(4):459-464.
- Singh R, Chouhan US, Purohit S, et al. Radiation processed amniotic membranes in the treatment of non-healing ulcers of different etiologies. *Cell Tissue Bank*. 2004;5(2):129-134.
- Robson MC, Krizek TJ. The effect of human amniotic membranes on the bacteria population of infected rat burns. *Ann Surg*. 1973;177(2):144-149.
- Bose B. Burn wound dressing with human amniotic membrane. *Ann R Coll Surg Engl*. 1979;61(6):444-447.
- Rao TV, Chandrasekharam V. Use of dry human and bovine amnion as a biological dressing. *Arch Surg*. 1981;116(7):891-896.
- Branski LK, Herndon DN, Celis MM, Norbury WB, Masters OE, Jeschke MG. Amnion in the treatment of pediatric partial-thickness facial burns [published online October 24, 2007]. *Burns*. 2008;34(3):393-399. doi:10.1016/j.burns.2007.06.007.
- Waikakul S, Chumniprasas K, Setasubon S, Vajaradul Y. Application of freeze-dried amniotic membrane: a control trial at the donor site of split-thickness skin grafting. *Bull Hosp Jt Dis Orthop Inst*. 1990;50(1):27-34.
- Martinez Pardo ME, Reyes Frias ML, Ramos Duron LE, et al. Clinical application of amniotic membranes on a patient with epidermolysis bullosa. *Ann Transplant*. 1999;4(3-4):68-73.
- Subrahmanyam M. Amniotic membrane as a cover or microskin grafts. *Br J Plast Surg*. 1995;48(7):477-478.
- Rejzek A, Weyer F, Eichberger R, Gebhart W. Physical changes of amniotic membranes through glycerolisation for the use as an epidermal substitute: light and electron microscope studies. *Cell Tissue Bank*. 2001;2(2):95-102.
- Prasad JK, Feller I, Thomson PD. Use of amnion for the treatment of Stevens-Johnson syndrome. *J Trauma*. 1986;26(10):945-946.
- Viard I, Wehrli P, Bullani R, et al. Inhibition of toxic epidermal necrolysis by blockade of CD95 with human intravenous immunoglobulin. *Science*. 1998;282(5388):490-493.
- Coassin M, Lambiase A, Micera A, Tirassa P, Aloe L, Bonini S. Nerve growth factor modulates in vitro the expression and release of TGF-beta1 by amniotic membrane [published online September 13, 2005]. *Graefes Arch Clin Exp Ophthalmol*. 2006;244(4):485-491.
- Koizumi NJ, Inatomi TJ, Sotozono CJ, Fullwood NJ, Quantock AJ, Kinoshita S. Growth factor mRNA and protein in preserved human amniotic membrane. *Curr Eye Res*. 2000;20(3):173-177.
- Solomon A, Wajngarten M, Alviano F, et al. Suppression of inflammatory and fibrotic responses in allergic inflammation by the amniotic membrane stromal matrix. *Clin Exp Allergy*. 2005;35(7):941-948.
- Li W, He H, Kawakita T, Espana EM, Tseng SC. Amniotic membrane induces apoptosis of interferon-gamma activated macrophages in vitro [published online August 16, 2005]. *Exp Eye Res*. 2006;82(2):282-292.
- Ramakrishnan KM, Jayaraman V. Management of partial-thickness burn wounds by amniotic membrane: a cost-effective treatment in developing countries. *Burns*. 1997;23(suppl 1):S33-S36.

Submissions

Clinicians, residents, and fellows are invited to submit cases of challenges in management and therapeutics to this section. Cases should follow the established pattern. Manuscripts should be prepared double-spaced with right margins non-justified. Pages should be numbered consecutively with the title page separated from the text (see Instructions for Authors [<http://archderm.ama-assn.org/misc/ifora.dtl>] for information about preparation of the title page). Clinical photographs, photomicrographs, and illustrations must be sharply focused and submitted as separate JPG files with each file numbered with the figure number. Material must be accompanied by the required copyright transfer statement (see authorship form [http://archderm.ama-assn.org/misc/auinst_crit.pdf]). Preliminary inquiries regarding submissions for this feature may be submitted to George J. Hruza, MD (ghruza@aol.com). Manuscripts should be submitted via our online manuscript submission and review system (<http://manuscripts.archdermatol.com>).